Quelle: http://manuscripta.at/?ID=30486
Copyright: Heiligenkreuz, Zisterzienserstift

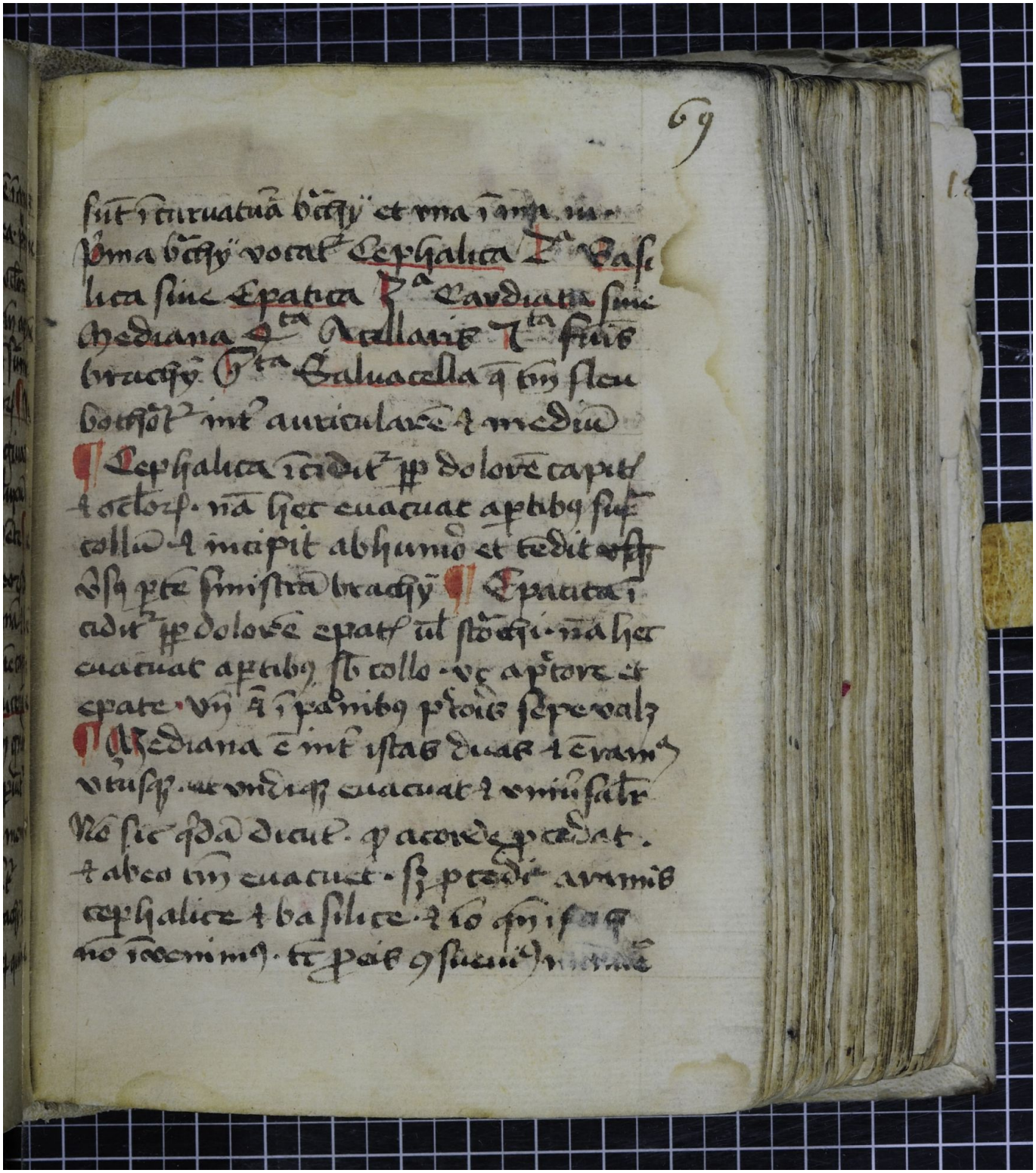

69

sut i curuatua bracij et vna i ima. in
ima bracij vocat Cephalica 1a Basi
lica siue Epatica 2a Cardiaca siue
Mediana 3ta Scellaris 4ta sinis
bracij. 5ta Saluacella q tm flebo
tomat int auriculare & medium
¶ Cephalica tedit pp dolore capitis
& oculorum. na hec euacuat a pribus sup
collum & incipit ab humero et tedit vsq
ad sq pte sinistra bracij ¶ Epatica i
edit pp dolore epatis id stomachi. na hec
euacuat a pribus sinistri collum. vt a pteris et
epate. vnde q i pribus pteris sepe valz
¶ Mediana e int istas duas & eram
vtusq. ut vnde ipsa euacuat & vnde satis
Nos sic qdam dicunt. q accide pcedat.
& a eo tm euacuet. si pcedit a venis
cephalice & basilice. & ro qm i sanq
no recenimus. tt patet q sicut in